

# *Facial structure and functional findings in patients with progressive muscular dystrophy (Duchenne)*

**L. Eckardt, DDS, and W. Harzer, DDS, PhD**

*Dresden, Germany*

The investigation of 15 patients who have a progressive muscular dystrophy of the Duchenne type (PMD) shows the affection of various groups of muscles of the stomatognathic system, studied by means of electromyography and mechanical force measurements. We observed the following deviations in patients with PMD; transversal overdevelopment and sagittal shortening of the dental arch; reduction of overbite and overjet; sagittal underdevelopment of the cranial, maxillary and mandibular base; retrusion of incisors; concave profile; increase in bizygomatic width; and a difference in time between the attack on the muscoli orbicularis oris and that on masticatory muscles. In our study, the activity of the jaw muscles diminished 2 years earlier compared with the perioral muscles. This, and also the enlargement of the hypotonic tongue, causes a transversal expansion of skull and dental arches. This expansion was strongly pronounced in the lower jaw; we invariably observed a posterior crossbite. In contrast to the transversal overdevelopment, we observed a sagittal underdevelopment of skeletal and dental parameters, as well as a retrusion of the incisors. The results of surface electromyography showed the affection of the masseter muscle in patients who had PMD. By means of the Fast-Fourier transformation, we observed a displacement of the median frequency as compared with the lower frequency range. (*Am J Orthod Dentofac Orthop* 1996;110:185-90.)

**T**he muscle dystrophy described by Duchenne in the last century, apart from being relatively frequent, is also the most malignant form of muscle dystrophy. It occurs only in males on the basis of x-chromosomal-recessive heredity and with a frequency of 1 in 4000. In most cases the disease manifests itself in the first or second year of life in a clumsy, unsteady gait. The muscular proprioceptive reflexes disappear at an early stage, and 5 to 10 years after the onset of the disease, patients are unable to walk. First, the glutei, the quadriceps, and the adductors are affected, and then the arm muscles, the shoulder girdle, and eventually the facial muscles.

Terminally, the muscular affection is generalized, breathing becomes insufficient, and most patients die even during the second decade of life, or at the latest, at beginning of the third, in consequence of recurrent infections of the upper airways.

Characteristic changes can be observed by electromyography. This reveals, in particular, the reduction of muscle fiber conduction velocity and the displacement of excitation spectra to lower frequencies.<sup>1</sup> The characteristic affection pattern of

muscles is reflected in analogous changes of the density of the affected muscle regions, as revealed by computer tomography.<sup>2,3</sup>

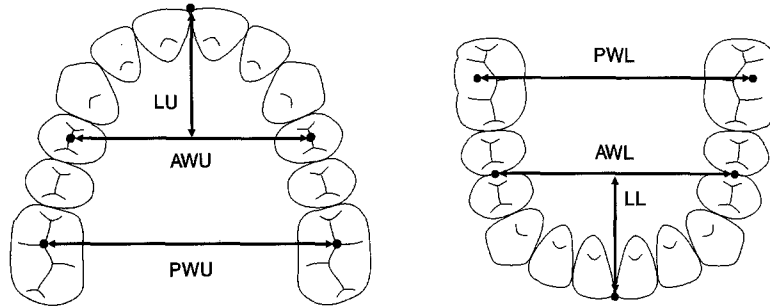
On the basis of heredity, investigations of conductors are described that show mild paraclinic changes in most cases. In addition to muscle deficiencies and pseudohypertrophies, changes in laboratory parameters, for example, an increase in creatinine kinase, also occur in such cases. Furthermore, abnormalities in electromyography, computer tomography, and chromosomal configuration are described.<sup>4-6</sup> Because the affection of the orofacial muscles is not important for determining prognosis of this illness, there are no more than a few publications on the subject in the field of orthodontics.

In patients with progressive muscular dystrophy (PMD), a transversal expansion of the dental arch in the upper and lower jaws that is accompanied by a posterior crossbite, a reduction of overbite, an increased occurrence of medial diastema in the upper and lower jaws, and a delayed dental development were described. A diminishing bite force and an enlargement of the tongue, which is ascribed to the pseudohypertrophy already mentioned, were also found.<sup>7-11</sup>

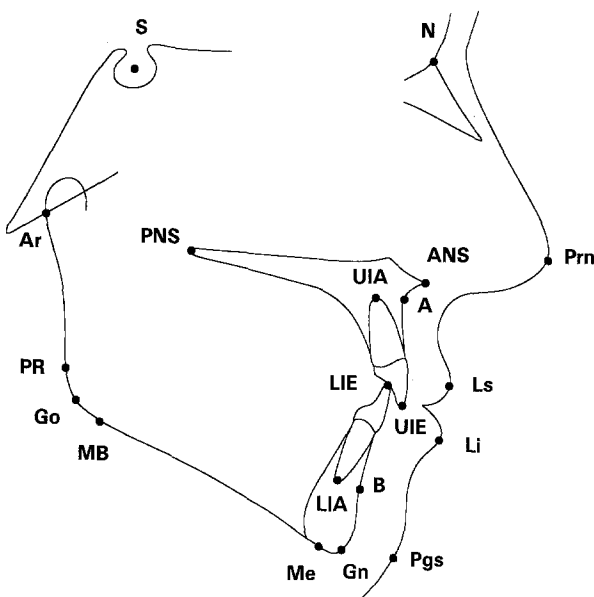
The aim of this investigation was to analyze the relationships between different periods of functional affection of facial muscle groups and the morphology of dental and skeletal structures.

Reprint requests to: Prof. Winfried Harzer, Poliklinik für Kieferorthopaedie, University of Dresden, Fetscherstr. 74, D01307, Dresden, Germany.

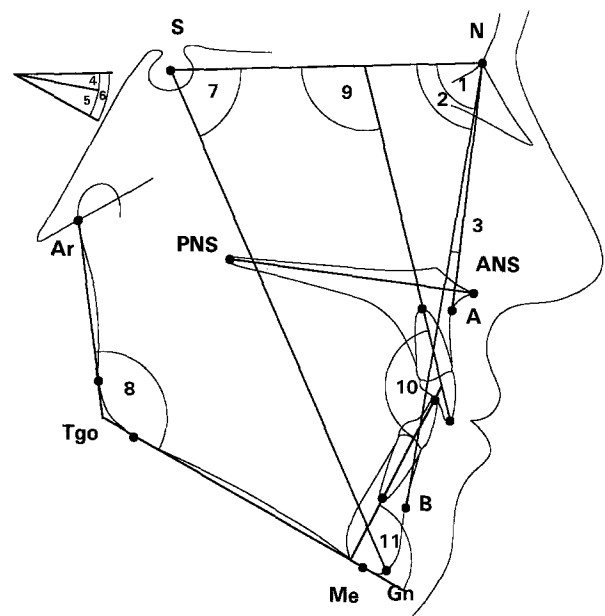
Copyright © 1996 by the American Association of Orthodontists.  
0889-5406/96/\$5.00 + 0 8/1/63124



**Fig. 1.** Landmarks and reference lines of Pont measurement: AWU, anterior width in upper jaw; PWU, posterior width in upper jaw; LU, length in upper jaw; AWL, anterior width in lower jaw; PWL, posterior width in lower jaw; LL, length in lower jaw.



**Fig. 2.** Landmarks: S, sella; N, nasion; A, A point; B, B point; Gn, gnathion; Me, menton; MB, mandibular base point; Go, gonion; PR, posterior ramus point; Ar, articulare; PNS, posterior nasal spine; ANS, anterior nasal spine; UIA, upper incisor apex; UIE, upper incisor edge; LIE, lower incisor edge; LIA, lower incisor apex; Prn, pronasale; Ls, labrale superius; Li, labrale inferius; Pgs, soft tissue pogonion.



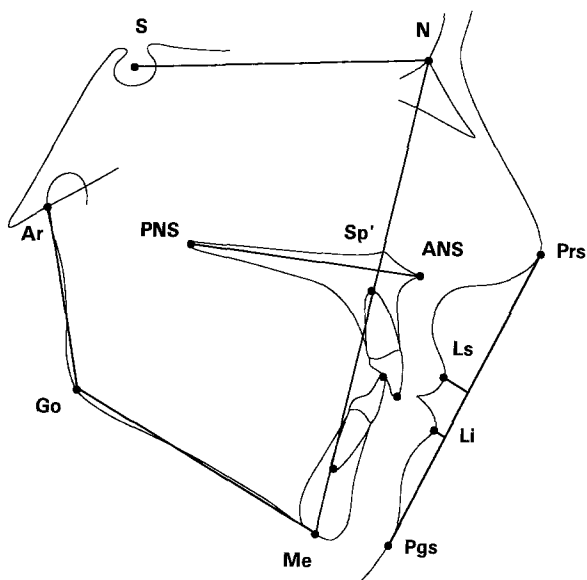
**Fig. 3.** Skeletal and dental angular measurements: 1. SNA angle, 2. SNB angle, 3. ANB angle, 4. SN/ANS-PNS angle, 5. SN/MeTgo angle, 6. ANS-PNS/MeTgo angle, 7. NS-Gn angle, 8. Me-Tgo-Ar angle, 9. UIE-UIA/SN angle, 10. UIA-UIE/LIE-LIA angle, 11. LIE-LIA/MeTgo angle.

## SUBJECTS AND METHOD

The study involved 15 male patients from 5 to 23 years old (mean, 11.7 years). All patients suffer from PMD of the Duchenne type. Diagnosis was corroborated by a muscle biopsy conducted within the neurologic scope. The clinical investigation was carried out at the Neurological Department of the University of Dresden.

The examinations were performed during the regular dental treatment of the patients. The observation period was between 1 and 5 years. The following records were made that included dental casts for the estimation of malocclusions, lateral cephalometric radiographs, measurements of the bizygomatic width, measurements of

bite and lip force, estimates of tongue size and motility, and, in some cases, bipolar surface electromyograms of the masseter and orbicularis oris muscle. The casts were measured by the Pont method (Fig. 1). As a control, we used the results of longitudinal testing of 103 pupils of Dresden schools.<sup>12</sup> The landmarks of the lateral radiographic analysis and the angle and length measurements are shown in Figs. 2, 3, and 4. The results published by Bhatia et al.<sup>13</sup> served as reference values. To assess transversal skull development, the bizygomatic width was measured by Berger's method.<sup>14</sup> The bite force was analyzed by means of an electromechanical dynamometer. Measurements were carried out in the left and right molar regions. Lip force was ascertained by Garliner's



**Fig. 4.** Linear measurements: Cranial base length (S-N), maxillary length (PNS-ANS), corpus length (Me-Go), ramus length (Go-Ar), upper face height (N-Sp'), lower face height (Sp'-Me), upper lip to esthetic plane (Ls-E plane), lower lip to esthetic plane (Li-E plane).

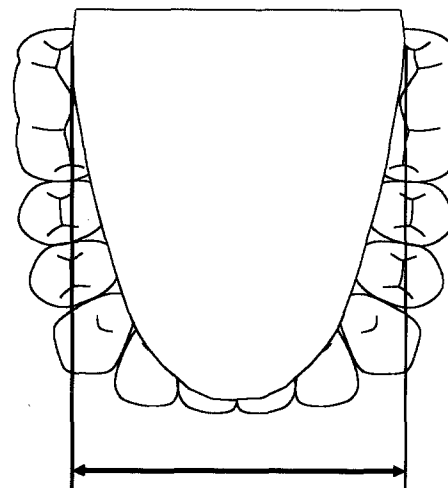
**Table I.** Mean value for dental arch parameters in patients with PMD and control patients

Variable	PMD, mean (mm)	Controls, mean (mm)	p-value
AWU	37.5	36.1	0.013
PWU	52.3	45.9	<0.001
LU	15.8	17.7	<0.001
AWL	39.2	36.4	<0.001
PWL	58.3	48.4	<0.001
LL	14.2	15.8	<0.001
Overbite	0.7	2.9	<0.001
Overjet	2.0	3.4	0.001

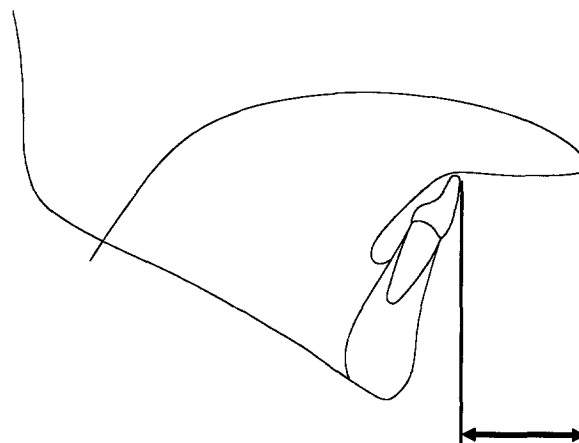
method.<sup>15</sup> A plastic screen with a diameter of 23 mm was held between the lips in the vestibulum, and the force required to remove the screen was measured.

As a parameter of tongue size, we used the greatest transversal extension of the tongue with the mouth slightly open (Fig. 5). The motility of the tongue was assessed on the basis of maximum tongue extension. The measuring length taken was the distance between the tip of the tongue and the foremost point of the lower dental arch at the maximum tongue extension (Fig. 6). In these cases, 12 boys of the same age also served as control patients.

The electromyogram investigation was recorded by maximum intercuspation (masseter muscle) and swallowing (orbicularis oris muscle). For the electromyographic comparison of patients with PMD with the patients of the control group, we used the Fast-Fourier analysis.



**Fig. 5.** Measurement of tongue size.



**Fig. 6.** Measurement of tongue motility.

Orthodontic patients of the same age and sex served as a control group. All results were evaluated with the *t* test.

## RESULTS

The sagittal and transversal dimensions of the dental arch showed significant changes in comparison with the control group. The width of the dental arch was increased in the upper and lower jaws. The expansion was greater in the molar region than in the premolar region. The mandible was more affected by the increase than the maxilla. In the sagittal dimension, the length of the dental arch was reduced in patients with PMD (Table I, Fig. 7). In all cases we noticed a posterior crossbite that resulted from the greater transversal dimension of the mandible as compared with that of the maxilla.

Cephalometric analysis produced the following findings (Table II): Retrognathic facial type during

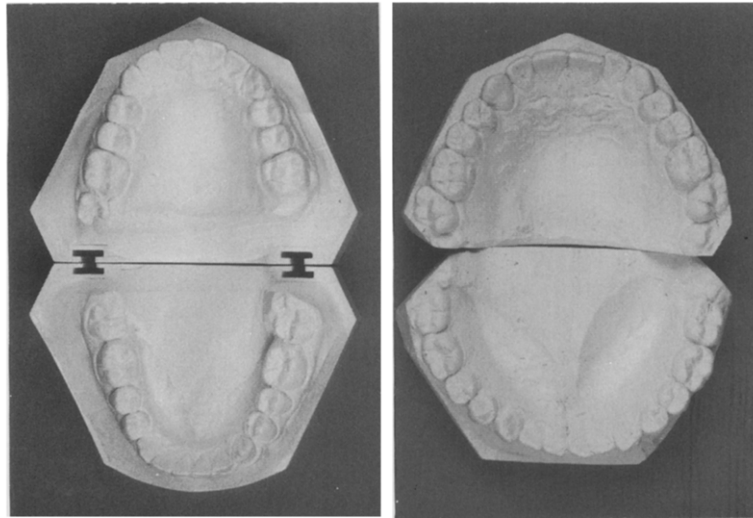


Fig. 7. Dental casts from patients with PMD (right) and control (left).

Table II. Mean value of cephalometric parameters in patients with PMD and control patients

Variable	PMD, mean	Controls, mean	p-value
SNA angle (degrees)	78.4	80.0	0.039
SNB angle (degrees)	75.4	76.5	0.076
ANB angle (degrees)	3.0	3.5	0.209
SN/ANS-PNS angle (degrees)	8.5	6.5	0.025
SN/Me-Tgo angle (degrees)	36.8	33.8	0.058
ANS-PNS/MeTgo angle (degrees)	28.3	27.3	0.287
NS-Gn angle (degrees)	69.1	67.4	0.084
Me-Tgo-Ar angle (degrees)	126.3	126.4	0.484
UIE-UIA/SN angle (degrees)	95.5	101.4	0.011
UIA-UIE/LIE-LIA angle (degrees)	142.9	133.0	0.006
LIE-LIA/MeTgo angle (degrees)	95.4	90.6	0.027
SN length (mm)	62.7	65.5	0.005
Maxillary length (PNS-ANS) (mm)	45.2	47.3	0.012
Corpus length (Me-Go) (mm)	60.1	63.2	0.008
Ramus length (Go-Ar) (mm)	36.7	38.5	0.036
Face height ratio (N-Sp'/Sp'-Me) (%)	78.4	83.7	0.004
LS-E plane (mm)	4.2	2.4	0.005
LI-E plane (mm)	3.5	2.1	0.011

reduction of the SNA and the SNB angles, increases in the SN/ANS-PNS, SN/MeTgo, and NS-Gn angles, shortening of the anterior cranial base and the maxillary, mandibular, and ramus lengths, increase in face height ratio (upper face height/lower face height), retrusion of the incisal axis in the upper and lower jaws, increase in inter-incisal angle, and a concave profile. The bizygomatic width was 7.9 mm greater than in the control group (Table III). Measurement of the tongue size showed extension and lower motility in patients who had PMD (Table III). Bite and lip force diminished after increasing to a certain point,

Table III. Mean value of the bizygomatic width with and tongue parameters in patients with PMD and control patients

Variable	PMD, mean (mm)	Controls, mean (mm)	p-value
Tongue size	47.0	41.4	0.019
Tongue motility	21.8	28.5	0.005
Bizygomatic width	116.9	109.0	0.002

whereas in the control group, both increased continuously throughout the period of investigation (Fig. 8). In patients who had PMD, the decrease in bite force began after the age of 8 years, i.e., 2 years earlier than the decrease in lip force. The electromyogram with Fast-Fourier analysis showed a pathologic pattern in the masseter muscle. The median frequency of the masseter muscle was located in the lower frequency range in patients who had PMD (mean, 77 Hz; SD, 27 Hz), by contrast to the frequencies for the control group (mean, 110 Hz; SD, 14 Hz). A comparison of the median frequencies of masseter muscle (mean, 77 Hz; SD, 27 Hz) and orbicularis oris muscle (mean, 101 Hz; SD, 21 Hz) in patients who had PMD showed a lower frequency for the masseter. This indicates that the masseter is subjected to earlier attack.

## DISCUSSION AND CONCLUSIONS

The most important finding is the interval of 2 years between the decrease in bite force and the decrease in lip force in patients who had PMD. The decrease in masseter muscle tonus near the molars, the enlarged tongue, and the predominance of

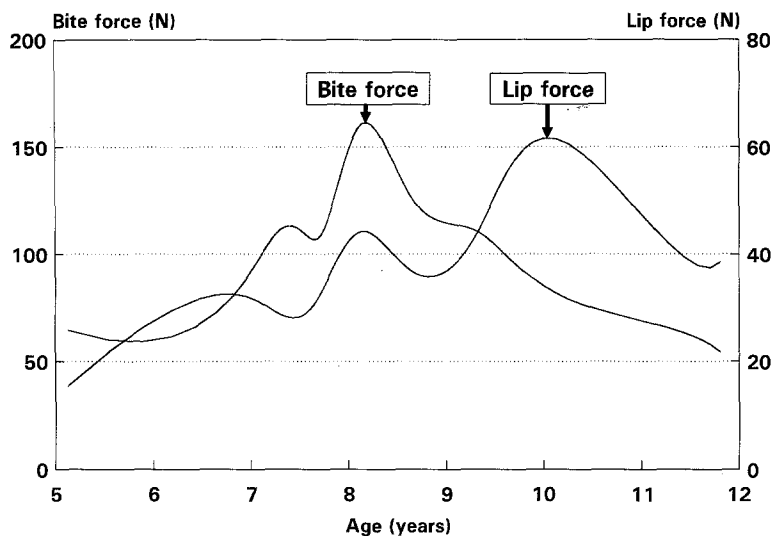


Fig. 8. Bite and lip force in patients with PMD.

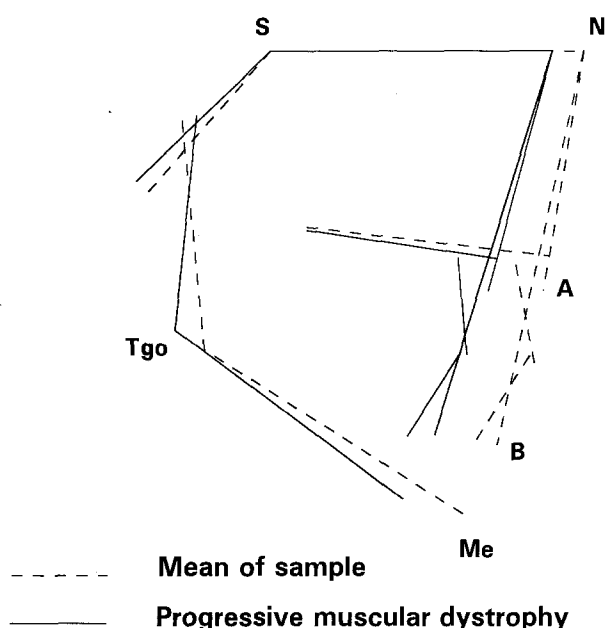
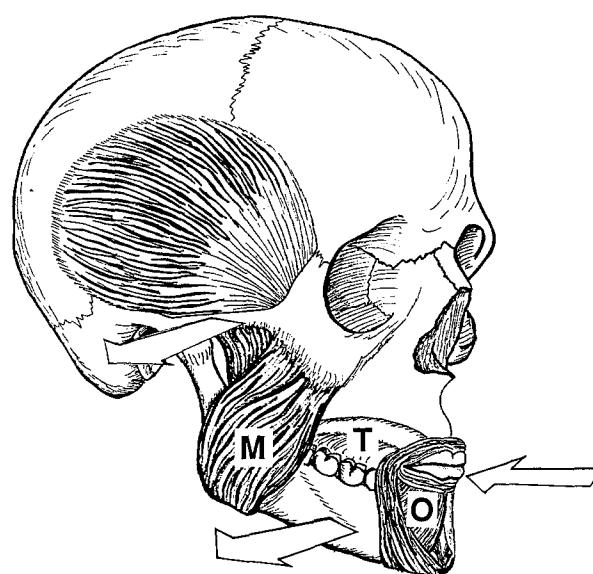


Fig. 9. Superposition of cephalograms from 10-year-old patient with PMD and same age controls, along SN line at sella point.

orbicularis oris muscle causes a reverse Perlchain effect that is known from the cause of maxilla compression.<sup>16</sup> The predominance of the cheek tonus, as compared with that of the tongue muscles in mouth breathing persons, results in compression of the upper jaw, accompanied by protrusion of the incisors. In the reverse case, weakness of the masticatory muscles permits unrestrained growth in the transversal dimension. This is also stimulated by



- M - masticatory muscles - weak
- O - orbicularis oris - normal
- T - tongue - weak and voluminous
- ⇒ change direction of morphology

Fig. 10. Representation of muscular and growth changes in patients with PMD.

the extended tongue. Fanghaenel<sup>17</sup> described such an effect on the basis of experimental resection of the temporalis muscle. In these cases he also observed an extensive transversal growth of the skull toward the resection side.<sup>17</sup>

By comparison, the pressure of the orbicularis

oris muscle leads to an upset of the maxilla and the mandible in a sagittal direction, in patients up to 10 years of age. The masseter muscle is at its weakest up to that age, and pressure from the orbicularis oris muscle is high. This can also be seen from the cephalometric radiographs (Fig. 9).

The role of the tongue is limited to mandibular expansion in a buccal direction, because functional motility is reduced. The protrusive effect near the incisors is inhibited by the perioral muscles. This shows that dental and skeletal structures are influenced, not only by the size of the tongue, but also by its function (Fig. 10).

Despite the reduction in overbite in patients who have PMD, we did not observe any such increase in lower facial height, as compared with upper facial height, as described in patients who have a myotonic dystrophy. This suggests differing specific affection patterns for PMD and myotonic dystrophy.<sup>18-20</sup>

These conclusions are doubtless evidence of the influence of muscles on the structure of the facial skeleton and thus of the importance of muscle balance. Functional approaches with muscle balance as the first treatment will be favored by these results. The results of electromyographic analysis will confirm this hypothesis. It can be concluded that the lack of activity of the masticatory muscles and the relatively increased tonus of the perioral muscles result in the sagittal underdevelopment and transversal overdevelopment of dental and skeletal structures. This effect of imbalance in the musculature on bone structure suggests a relationship between the function and the shape of the facial bone complex. A prerequisite for the treatment of sagittal and vertical malocclusion is the normalization of muscle function.

## REFERENCES

1. Frascarelli M, Rocci, Feola I. EMG computerized analysis of localized fatigue in Duchenne muscular dystrophy. *Muscle Nerve* 1988;11:757-61.
2. Gellerich I, Koch RD. Computerized tomography findings in malignant progressive Duchenne muscular dystrophy. *Psychiatr Neurol Med Psychol* 1990;42:282-90.
3. Gibertoni M, Colombo A, Schoenhuber R, Galassi G, Calo M, Crisi G. Muscle CT, biopsy and EMG in diagnosis of neuromuscular diseases. *Ital J Neurol Sci* 1987;8:51-3.
4. Kawai M, Kumimoto M, Kamakura K. Asymmetrical patchy muscle involvement in manifesting carriers of Duchenne muscular dystrophy—computed tomographical and histological study. *Rinsho Shinkeigaku* 1989;29:23-9.
5. Mamoli B, Toiff K, Vormittag W, Pateisky K. Determination of average fiber density (single fiber lead), quantitative electromyography and serum CK in the detection of Duchenne carriers. *EEG EMG Z Elektroenzephalogr Elektromyogr Verwandte Geb* 1983;14:36-8.
6. Toulouse P, Coatrieux JL, LeMarec B. An attempt to differentiate female relatives of Duchenne type dystrophy from healthy subjects using an automatic EMG analysis. *J Neurol Sci* 1985;67:45-55.
7. Erturk N, Dogan S. The effect of neuromuscular diseases on the development of dental and occlusal characteristics. *Quintessence Int* 1991;22:317-21.
8. Ghafari J, Cark RE, Shofer FS, Berman PH. Dental and occlusal characteristics of children with neuromuscular diseases. *Am J Orthod Dentofac Orthop* 1988; 93:126-32.
9. Manhartberger C, Haberfeller H, Richter M. Kiefer- und Gebissanomalien bei der progressiven Muskeldystrophie (Erb-Duchenne). *Z Stomat* 1987;84:299-306.
10. White R, Sacker AM. Effects of progressive muscular dystrophy on occlusion. *J Am Dent Assoc* 1954;49:449-56.
11. Watanabe M, Shimizu K, Nakata S, Watanabe K, Morishita T, Miyoshino S. Morphological and functional analysis of dento-orofacial complex in monozygotic twins with Duchenne type muscular dystrophy. *Nippon Kyosei Shika Gakkai Zasshi* 1990;49:522-37.
12. Ullmann J, Scherf M. Kieferorthopaedische Laengsschnittuntersuchungen an 103 Dresdner Schulkindern zwischen dem 7. und 17. Lebensjahr. [Thesis] Dresden: University of Dresden, 1991.
13. Bhatia SN, Leighton BC. A manual of facial growth. Oxford: Oxford University Press, 1993.
14. Berger H. Constitution, heredity and orthodontia. *Am J Orthod Oral Surg* 1938;24:136-50.
15. Garliner D. Myofunktionelle Therapie in der Praxis. Muenchen: Verl Med Schrifttum, 1982:170.
16. Reichenbach E, Breckl H. Zahnraetzliche Fortbildung: Kieferorthopaedie Klinik und Therapie. Leipzig: Johann Ambrosius Barth Verlag, 1967:70.
17. Fanghaenel J, Koester D, Miertgwa J, Schumacher GH. Craniofacial growth under the influence of blood supply. *Anat Anz* 1987;164:95-101.
18. Graziot E, Bornstein N, Lieberman M, Servaty V, Gross M, Korocyn AD. The stomatognathic system in myotonic dystrophy. *Eur J Orthod* 1987;9:160-4.
19. Kiliaridis S, Meijers C, Thilander B. Muscle function and craniofacial morphology: a clinical study in patients with myotonic dystrophy. *Eur J Orthod* 1989;11: 131-8.
20. Kreiborg S, Leth Jensen B, Moller E, Bjork A. Craniofacial growth in a case of congenital muscular dystrophy. *Am J Orthod Dentofac Orthop* 1978;74:207-15.