

## 3D-CT evaluation of facial asymmetry in patients with maxillofacial deformities

Masahito Maeda, DDS,<sup>a</sup> Akitoshi Katsumata, DDS, PhD,<sup>b</sup> Yoshiko Arijii, DDS, PhD,<sup>c</sup>  
 Atsushi Muramatsu, DDS,<sup>d</sup> Kenji Yoshida, DDS, PhD,<sup>e</sup> Shigemi Goto, DDS, PhD,<sup>f</sup>  
 Kenichi Kurita, DDS, PhD,<sup>g</sup> Eiichiro Arijii, DDS, PhD<sup>h</sup>

**Objective:** The aims of this study were to characterize the symmetrical features of patients with facial deformities and to suggest a classification system for facial asymmetry based on 3-dimensional-computed tomography (3D-CT) evaluation.

**Study design:** Preoperative CT images were investigated for 49 patients with maxillofacial deformities. Asymmetry indices were calculated for some landmarks in the maxilla, mandibular body and the mandibular ramus regions.

**Results:** Asymmetry was observed most frequently in the mandibular body region. The subjects were divided into 3 groups. Subjects without any asymmetry in the 3 regions were classified as Group I (44.9%). Groups II or III were defined for subjects without or with maxillary region asymmetry, respectively, and they were subcategorized. In Group IIA (8.2%), asymmetry was shown solely in the mandibular body region, and in Group IIB (18.4%), additional asymmetry was shown in the mandibular ramus region. Group IIIA (6.1%) showed asymmetry only in the maxillary region, and Group IIIB (22.4%) showed asymmetry in all 3 regions.

**Conclusion:** The 3D-CT classification for facial asymmetry has the potential to replace the conventional cephalometric classification.

(Oral Surg Oral Med Oral Pathol Oral Radiol Endod 2006;xx:xxx)

## INTRODUCTION

Cosmetic improvement, such as recovery of facial symmetry, is a matter of great concern to patients with maxillofacial deformities. Facial asymmetry is concomitantly observed in 21 to 67% of patients who complain of protraction or retraction of the jaws.<sup>1-4</sup> Cephalometric radiography is the primary method that is used for diagnosing maxillofacial deformities including facial asymmetry,<sup>5-9</sup> and is an effective tool for planning orthodontic treatment or orthognathic surgery

and for evaluating the results. However, the reliability of frontal cephalometric measurement for facial asymmetry evaluation is limited because some landmarks are difficult to identify due to overlap.<sup>10</sup> Moreover, head positioning, which is usually determined based on the external auditory meatus, may modify the symmetry factors of other landmarks. Recent progress in orthognathic surgery and orthodontic treatment has led to an increasing demand for more advanced imaging information including 3D images. Although methods that use frontal and lateral cephalograms have been proposed to obtain 3 dimensional images,<sup>11-13</sup> they possess limitations because landmarks cannot be used when they are not well-identified on both cephalograms.

Three-dimensional CT (3D-CT) imaging may resolve these problems and is effective for the diagnosis and treatment of patients with maxillofacial deformities.<sup>14-17</sup> Although the accuracy of 3D-CT measurements is sufficiently high,<sup>18,19</sup> there is no well-established 3D evaluation procedure for facial asymmetry. We have therefore developed a 3D-CT imaging procedure that employs a technique based on three-dimensional coordinate point evaluation.<sup>17</sup> We defined the anatomical landmarks on 3D-CT images by modifying the cephalometric measurement points and determined the range of asymmetry indices for normal (symmetry) subjects.<sup>17</sup>

The purposes of this retrospective study were to characterize the symmetrical features of patients with

<sup>a</sup>Postgraduate Student, First Department of Oral and Maxillofacial Surgery, Aichi-Gakuin University School of Dentistry, Nagoya Japan.

<sup>b</sup>Associate Professor (Former family name is Kawamata), Department of Oral Radiology, Asahi University School of Dentistry, Gifu Japan.

<sup>c</sup>Assistant Professor, Department of Oral Radiology, Aichi-Gakuin University School of Dentistry, Nagoya Japan.

<sup>d</sup>Postgraduate Student, Department of Orthodontics, Aichi-Gakuin University School of Dentistry, Nagoya Japan.

<sup>e</sup>Professor, First Department of Oral and Maxillofacial Surgery, Aichi-Gakuin University School of Dentistry, Nagoya Japan.

<sup>f</sup>Professor, Department of Orthodontics, Aichi-Gakuin University School of Dentistry, Nagoya Japan.

<sup>g</sup>Professor, First Department of Oral and Maxillofacial Surgery, Aichi-Gakuin University School of Dentistry, Nagoya Japan.

<sup>h</sup>Professor, Department of Oral and Maxillofacial Radiology, Aichi-Gakuin University School of Dentistry, Nagoya Japan.

1079-2104/\$ - see front matter

© 2006 Elsevier Inc. All rights reserved.

doi:10.1016/j.tripleo.2005.10.057

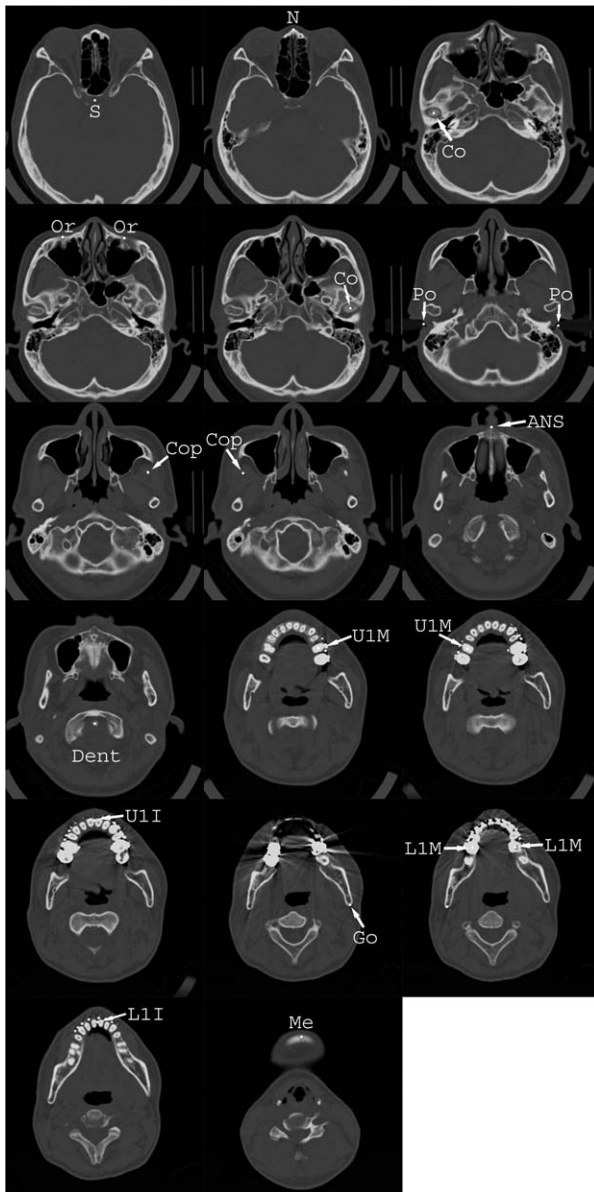


Fig. 1. Anatomical landmarks for 3D-CT are plotted on the axial CT images.

facial deformities in comparison normal subjects and to suggest a classification system for facial asymmetry based on 3D-CT evaluation, especially for mandibular prognathism.

## MATERIAL AND METHODS

### Subjects

Ninety-six patients were diagnosed as maxillofacial deformities and underwent orthognathic surgery at the 1st Department of Oral and Maxillofacial Surgery of Aichi-Gakuin University Dental Hospital from October 1998 to March 2002. All patients were preoperatively

Table 1. Landmarks for 3D-CT

Landmark	On CT image
Landmarks for the determination of the reference planes	
S (Sella)	Center of the pituitary fossa
N	Nasofrontal suture at the midline
Dent (Dens)	The most superior point of odontoid process of the epistropheus
Landmarks for the evaluation of facial asymmetry	
Or (Orbitale)	The mid-point of the infra-orbital margin
Po (Porion)	The superior surface of the external auditory meatus
ANS	Anterior nasal spine
U1I	The crest of the alveolar ridge between the upper central incisors
U1M	The pulp cavity at the crown of the upper first molar
L1I	The crest of the alveolar ridge between the lower central incisors
L1M	The pulp cavity at the crown of the lower first molar
Me (Menton)	The lower border of the mid-mandibular suture
Co (Condyle)	The most superior point of the condyle
CoP	The most superior point of the coronoid process
Go (Gonion)	The most inferior and posterior points at the angles of the mandible

examined by CT to simulate the surgery. Among them, 47 were excluded because they did not match the following selection criteria.

1. Scanning planes included from the nasal bone to the chin.
2. Images showed sufficient quality without severe metal- and/or motion artifacts.
3. The 1st molars and central incisors were preserved on the right and left sides of the upper and lower jaws.
4. Teeth position was maintained at centric occlusion during CT scanning.

As a result, 49 patients including 15 males and 34 females with a mean age of  $23.0 \pm 5.3$  years were selected for the following analyses. The majority of the excluded subjects were those with a cleft palate, because the scan area did not include the mandible. The chief complaints of these 49 patients were protrusion of the maxilla (4 patients) and of the mandible (36 patients), facial asymmetry (6 patients) and open bite (3 patients). According to the skeletal classification deter-

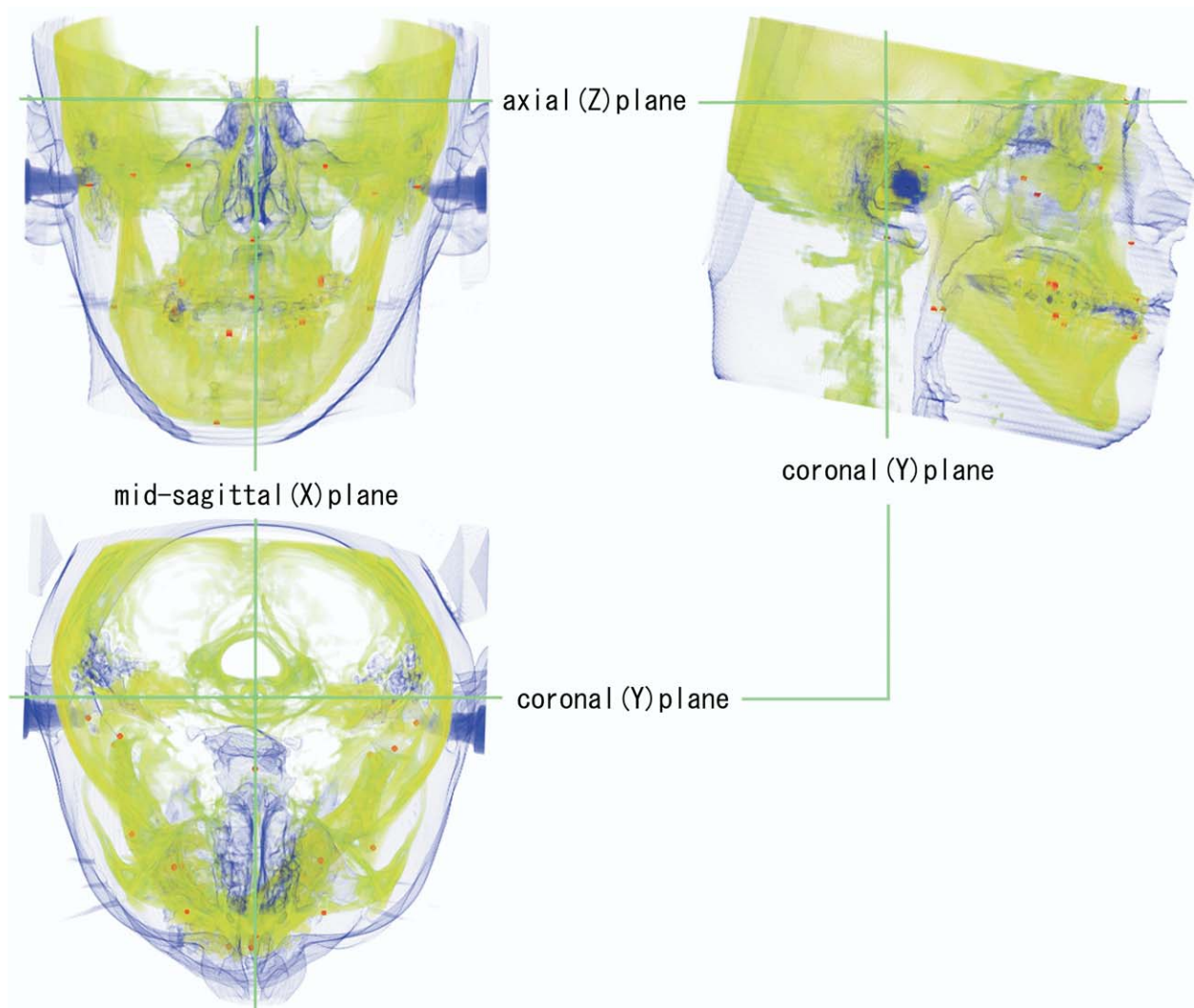


Fig. 2. Three-dimensional reference planes in the semi-transparent 3D-CT images that show the facial surface, hard tissue structures and drawn anatomical points (red points). Mid-sagittal (X), coronal (Y) and axial (Z) reference planes (axes) are shown in green.

mined by the plaster model and lateral cephalograms, 43 patients showed Class 3 deformity. Class 2 deformity was observed in 5 patients and the remaining patient was Class 1.

### CT image data acquisition

The CT images were obtained with a Somatom Art (SiemensAG, Erlangen, Germany) using a conventional sequential scan technique. The exposure conditions were set at 130kV and 100mA, and the slice thickness of an axial image was 2 mm without slice gaps. The image matrix size was 512 x 512 and the pixel size was 0.3 mm. Scans were performed with reference to the occlusal plane or the Frankfort horizontal plane. The resultant slice image data was stored

on a magneto-optical (MO) disk and then converted to create 3D-CT images for co-ordinate point evaluation using a Macintosh computer system (Power Macintosh G3, Apple Computer Inc., Cupertino, Calif.). The 16 bit CT image data was converted into 8 bit tagged image file format (TIFF) with the window setting for observing hard tissue structures.

### Evaluation of the facial asymmetry

Facial asymmetry was evaluated based on the previously-reported procedures.<sup>17</sup> Anatomical landmarks for 3D-CT, which were modified from the cephalometric measurement points, were plotted on axial slice images using an image editing software (Adobe Photoshop,

Adobe Systems Inc., U.S.A) (Fig. 1). Anatomical landmarks for 3D-CT are summarized in Table 1.

Semi-transparent 3D images that enable viewing of the facial surface, hard tissue structures and drawn anatomical points were created with a three-dimensional imaging software system (VoxBlast, VayTek, Inc., Fairfield, Iowa) and a volume rendering technique.

Three reference planes were defined to assess facial symmetry: the mid-sagittal (X-), coronal (Y-) and axial (Z-) planes. The mid-sagittal (X-) reference plane was defined as the plane containing the points S, N, and Dent, the axial (Z-) plane was defined as the plane perpendicular to the X-plane and included the points S and N, and the coronal (Y-) plane was defined as the plane perpendicular to the X- and Z-planes that included the S point (Fig. 2). For a certain point on a 3D-CT image, the coordinates (dx, dy, dz) could be determined as the distances from the reference planes.

The asymmetry indices of the bilateral landmarks, Or, Po, Go, U1M, L1M, Co, and CoP, were calculated using the following formula, where R = right, L = left:

$$\text{Asymmetry index} = \sqrt{(Rdx - Ldx)^2 + (Rdy - Ldy)^2 + (Rdz - Ldz)^2}$$

For solitary landmarks, Me, U1I, L1I, ANS that are located near the midline, only dx was measured and was defined as the asymmetry index. These indices were grouped based on the locations of the landmarks. The landmarks of 5 indices, ANS, U1I, Or, Po, and U1M, were located in the superior region including the maxilla. This region was defined as the maxillary region. The indices related to the mandible were divided into the mandibular body, L1I, Me, and L1M, and the mandibular ramus, Co, CoP, and Go region groups.

Asymmetry indices of the deformity subjects were evaluated in comparison with the diagrammatic chart based on the mean and standard deviations of those of the normal (symmetry) subjects (Fig. 3).<sup>17</sup> These normal controls consisted of 16 subjects (12 males and 4 females) and were retrospectively selected from patients who had undergone CT examinations for the lesions other than maxillofacial deformity, such as maxillofacial injury without fracture and diffuse inflammation. They also met the age and the selection criteria of the subjects that were analyzed in the present study. For each anatomical landmark, the index was classified into one of 3 categories, "Symmetry", "Asymmetry" and "Marked asymmetry". "Symmetry" was defined as the index within the mean plus the standard deviation of normal subjects (baseline), "Asymmetry" was between the values of the baseline and twice the baseline, and "Marked asymmetry" was defined as the value beyond twice the baseline.

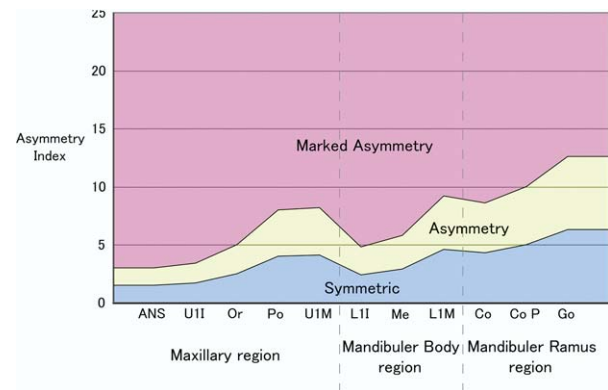


Fig. 3. A diagrammatic chart of normal (symmetry) subjects. The degree of asymmetry was determined based on this chart for each asymmetry index.

Regional assessments were performed for the maxilla, mandibular body and mandibular ramus regions. The region was regarded as having positive asymmetry when one or more indices evaluated showed "Marked asymmetry" or when two or more indices for the mandibular body and ramus regions or three or more indices for the maxillary region showed "Asymmetry".

## RESULTS

### Asymmetry index of each landmark

The asymmetry index of each landmark is summarized for the subjects showing mandibular prognathism and all kinds of deformities in Tables 2 and 3, respectively. In more than half of the mandibular prognathism subjects, the indices related to the mandibular body (L1I, Me, L1M) showed "Asymmetry" or "Marked asymmetry". The highest incidences of "Asymmetry" and "Marked asymmetry" were observed in the indices of L1M and Me, respectively. Conversely, the index of ANS, which was located in the maxillary region, showed the highest incidence of "Symmetry". These tendencies were also shown for all patients (Table 3).

### Reginal assessment

The mandibular body region showed the highest incidence of positive asymmetry, followed by the mandibular ramus and maxillary regions (Table 4).

### Classification of facial asymmetry

Based on the regional assessment, all subjects could be placed into 5 groups (Table 5), and initially they were divided into three Groups. Subjects without regions showing positive asymmetry were categorized as Group I, and those without or with positive asymmetry in the maxillary region were Groups II or III, respectively. Groups II and III could be divided into two



**Table II.** Degree of asymmetry of each index in 43 mandibular prognathism subjects

Region	Index	Degree of Asymmetry (Number of subjects)		
		Symmetry	Asymmetry	Marked asymmetry
Maxilla	Or	26 (60.5%)	13 (30.2%)	4 (9.3%)
	Po	24 (55.8%)	17 (39.5%)	2 (4.7%)
	ANS	36 (83.7%)	5 (11.6%)	2 (4.7%)
	UII	26 (60.5%)	14 (32.6%)	3 (7.0%)
	UIM	23 (53.5%)	12 (27.9%)	8 (18.6%)
Mandibular body	LII	20 (46.5%)	11 (25.6%)	12 (27.9%)
	LIM	13 (30.2%)	18 (41.9%)	12 (27.9%)
	Me	18 (41.9%)	10 (23.3%)	15 (35.9%)
	Co	24 (55.8%)	17 (39.5%)	2 (4.7%)
Mandibular ramus	CoP	24 (55.8%)	16 (37.2%)	3 (7.0%)
	Go	23 (53.5%)	17 (39.5%)	3 (7.0%)

**Table III.** Degree of asymmetry of each index in all deformity subjects (n = 49)

Region	Index	Degree of asymmetry (Number of subjects)		
		Symmetry	Asymmetry	Marked asymmetry
Maxilla	Or	31 (63.3%)	14 (28.6%)	4 (8.2%)
	Po	26 (53.1%)	21 (42.9%)	2 (4.1%)
	ANS	42 (85.7%)	5 (10.2%)	2 (4.1%)
	UII	30 (61.2%)	16 (32.7%)	3 (6.1%)
	UIM	25 (51.0%)	16 (32.7%)	8 (16.3%)
Mandibular body	LII	24 (49.0%)	13 (26.5%)	12 (24.5%)
	LIM	14 (28.6%)	22 (44.9%)	13 (26.5%)
	Me	21 (42.9%)	11 (22.4%)	17 (34.7%)
	Co	30 (61.2%)	17 (34.7%)	2 (4.1%)
Mandibular ramus	CoP	26 (53.1%)	19 (38.8%)	4 (8.2%)
	Go	25 (51.0%)	19 (38.8%)	5 (10.2%)

**Table IV.** Regional assessment (Number of regions with positive asymmetry)

Region	Mandibular prognathism subjects	
	(n = 43)	All subjects (n = 49)
Maxilla	11 (23.3%)	14 (28.6%)
Mandibular body	20 (46.5%)	24 (49.0%)
Mandibular ramus	17 (39.5%)	20 (40.8%)

Region with positive asymmetry: region with one or more indices showing "Marked asymmetry", or with two or more indices for the mandibular body and ramus regions or three or more indices for the maxillary region showing "Asymmetry"

subgroups. Group IIA showed positive asymmetry solely in the mandibular body region and the Group IIB showed positive asymmetry both in the mandibular body and ramus regions. Group IIIA showed the positive asymmetry only in the maxillary region, and Group IIIB showed positive asymmetry in the maxillary region together with the mandibular body and ramus regions. No subjects showed positive asymmetry solely in the mandibular ramus, and there were no subjects

that had a positive maxillary region with one of the mandibular region's asymmetry. Consequently, more than half of the patients showed facial asymmetry. "Of 6 subjects who chiefly complained of facial asymmetry, a subjects was classified into Group I, 2 subjects into Group IIB and 3 subjects into Group IIIB." Typical images and charts are shown in [Figures 4 to 6](#).

## DISCUSSION

CT allows viewing of the soft tissue and skeletal structures in three dimensions.<sup>16</sup> Its accuracy is sufficiently high for the linear measurement with CT-based 3D images.<sup>18,19</sup> Cavalcanti et al.<sup>18</sup> investigated the accuracy by comparing the linear measurement results on volume rendering 3D-CT images with those of physical measurements performed on cadavers. They concluded that the difference between two measurements was minimal and that the accuracy of the 3D image was high. In recent years, this has been improved upon with helical CT machines.<sup>14</sup> Utilizing these advantages, we developed a 3D-CT imaging system for the evaluation of facial asymmetry and verified the high reproducibility of the system for linear measurements.<sup>17</sup>

**Table V.** Classification of facial asymmetry

Classification	Region			Mandibular prognathism subjects (n = 43)	All subjects (n = 49)
	Maxilla	Mandibular body	Mandibular ramus		
Group I	-	-	-	20 (46.5%)	22 (44.9%)
Group IIA	-	+	-	3 (7.0%)	4 (8.2%)
Group IIB	-	+	+	8 (18.6%)	9 (18.4%)
Group IIIA	+	-	-	3 (7.0%)	3 (6.1%)
Group IIIB	+	+	+	9 (21.0%)	11 (22.4%)

+: region with one or more indices showing “Marked asymmetry”, or with two or more indices for the mandibular body and ramus regions or three or more indices for the maxillary region showing “Asymmetry”

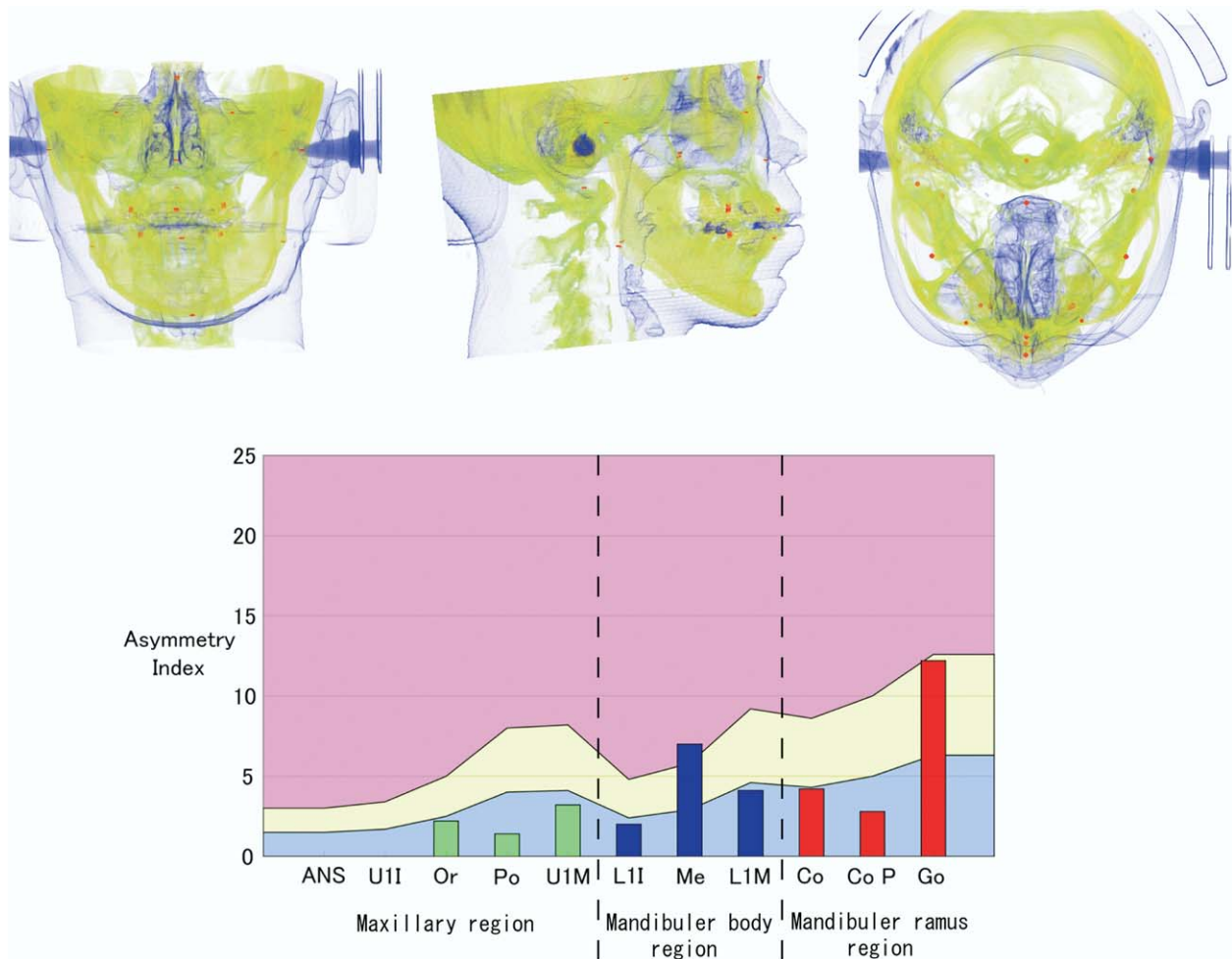


Fig. 4. 3D-CT images and a diagrammatic graph of a Group IIA subject. The index of Me shows “Marked asymmetry” and the Go shows “asymmetry”. However other indices were not beyond twice the baseline.

To evaluate the degree of asymmetry, asymmetry indices of patients were compared with those of normal subjects.<sup>17</sup> Symmetry degrees were determined in comparison with a diagram which showed the mean and the standard deviation of normal subjects. In the present

study, the diagram was modified and arranged to evaluate regional asymmetry. The landmarks for 3D-CT were selected based on cephalometric measurement points because the quantity of accumulated data concerning the cephalometric measurements is probably

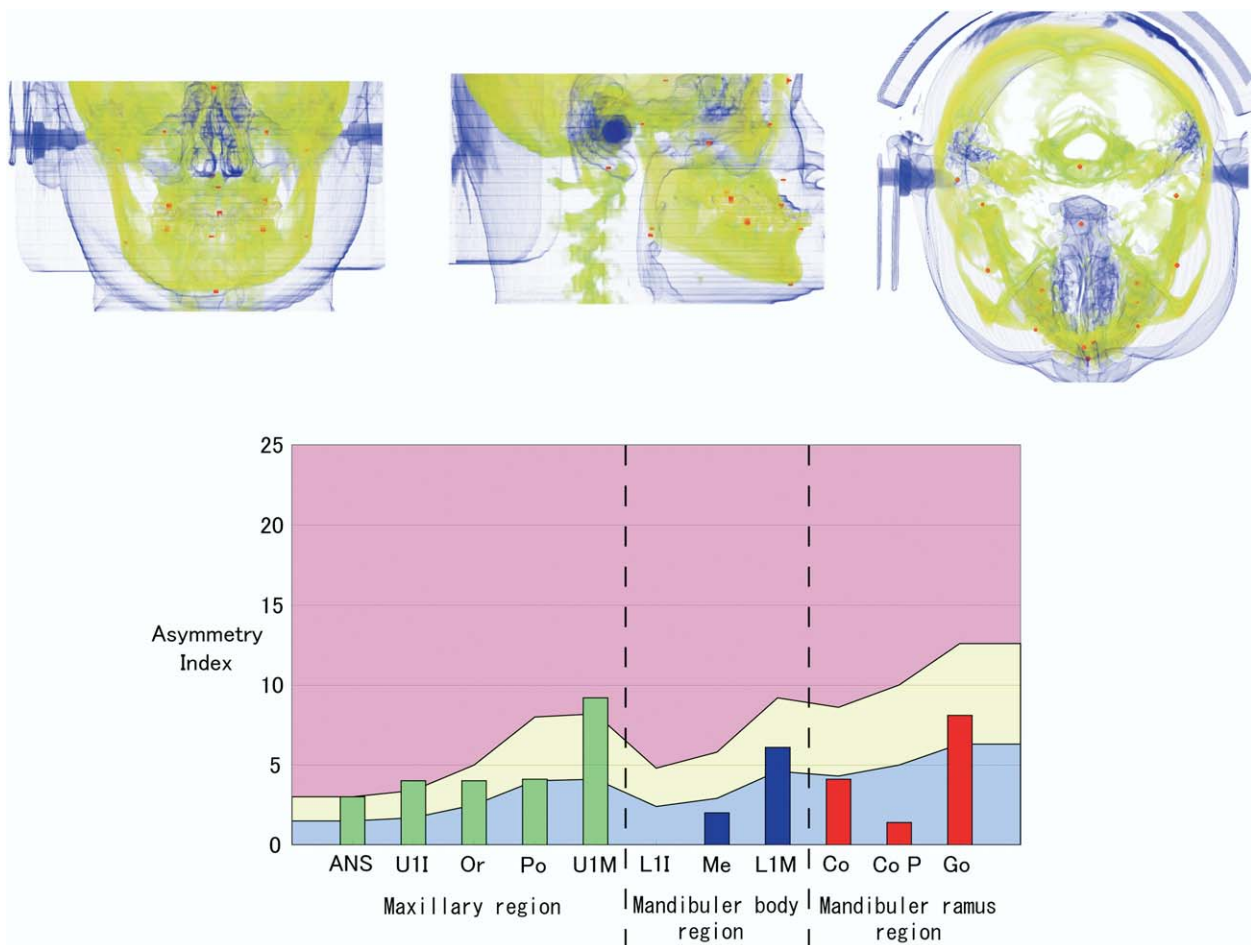


Fig. 5. 3D-CT images and a diagrammatic graph of a Group IIIA subject. The indices U1I and U1M showed “Marked asymmetry”. In the mandibular regions, only the L1M indicated “asymmetry”. Similarly, in the mandibular ramus region, only the Go showed “asymmetry”.

also effective for 3D-CT evaluation. This 3D coordinate system can be applied to data obtained by different CT scanners and to calculations performed by different software.

Traditionally, the appearance of facial asymmetry in patients with maxillofacial deformities has been investigated using frontal cephalographic images.<sup>1-4</sup> In these reports, the incidences of facial asymmetry were from 21 to 67 % in patients with facial deformities. This wide variation is probably due to differences in the diagnostic criteria of “maxillofacial deformity” and “facial asymmetry” in addition to differences in race and patients distributions, such as gender and age. Severt and Proffit<sup>3</sup> reviewed the clinical records of 1,460 maxillofacial deformity patients in North Carolina and reported that 34% had facial asymmetry. In the Japanese population, Tani et al<sup>2</sup> reviewed PA cephalometric images of 239 patients with maxillofacial deformities, and

reported that 28% were concomitant with facial asymmetry. Fukushima et al<sup>1</sup> also evaluated Japanese maxillofacial deformity patients and found that the incidence was 67%. In the present study where all patients underwent surgical treatments, the rate of facial asymmetry was 55.1%. Taking the severity of the deformities into account, the rate of the present study might not be too high in comparison with other reports. For the Class III malocclusion subjects, a higher prevalence of facial asymmetry was reported at 40% by Severt and Proffit.<sup>3</sup> Haraguchi et al.<sup>20</sup> investigated 220 subjects with Class III malocclusion and emphasize the high prevalence of facial asymmetry determined on the basis of the landmark deviation from the center line. Approximately 80% of the subjects showed over 2mm deviation in the Me, while the subjective evaluation revealed that a half had facial asymmetry.

Patterns of facial asymmetry are usually categorized

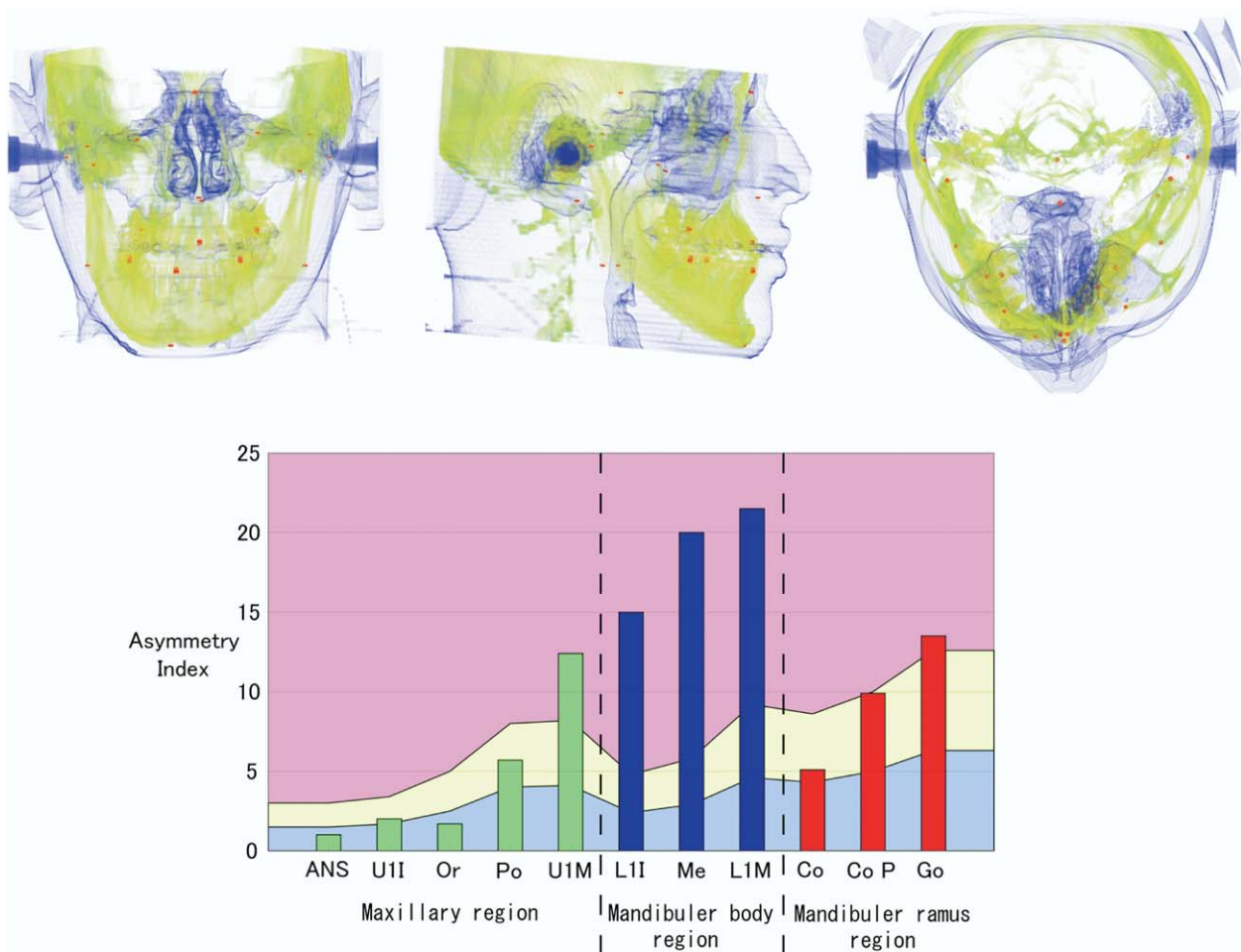


Fig. 6. 3D-CT images and a diagrammatic graph of a Group IIIB subject. All three regions were regarded as “positive asymmetry”.

according to asymmetrical regions.<sup>1,2</sup> Based on the cephalometric measurements, 80% of the asymmetry was solely observed in the mandible, and the maxilla and mandible were involved in the remaining 20% of the cases.<sup>1</sup> Another report described similar results with 64% in the mandible and 36% in the maxilla and mandible.<sup>2</sup> In these reports, there were no patients who showed asymmetry solely in the maxilla. In the present study, 3 (6.1%) patients showed asymmetry solely in the maxilla, and this discrepancy is probably due to the method of evaluation. The 3D-CT might have higher sensitivity than PA cephalometric imaging for diagnosing maxillary asymmetry. On PA cephalograms, the asymmetry of the anteroposterior direction, such as the distance between a landmark and the coronal reference plane, could not be evaluated. The definition of the reference plane or line also has a significant effect on symmetry evaluation. The mid-sagittal plane was initially determined with reference to the S, N and Dent

landmarks on 3D-CT measurement, while the horizontal reference line was firstly determined based on the superiorly located landmarks followed by the vertical line in the cephalometric measurement. Furthermore, the identification of the landmarks by which the symmetry indices were calculated for the maxilla were somewhat difficult on cephalograms because several structures were superimposed in this region. Conversely, the 3D-CT allows us to measure absolute dimensions and to produce three-dimensional coordinates. Also, for the mandible, the asymmetry could not be assessed in the postero-anterior dimension on PA cephalograms. Although the asymmetry of the ramus is usually evaluated by the difference between the height of both sides on cephalograms,<sup>21</sup> there was no data available including that for the antero-posterior asymmetry assessment. On 3D-CT, we therefore tried to assess the mandible in two different regions for more detailed analysis, and consequently the asymmetry was



also verified in the ramus. However, it was more frequently observed in the mandibular body region than in the ramus region. All patients with ramus asymmetry had accompanying the body asymmetry. The evaluation of the ramus may influence the choice of treatment.<sup>21,22</sup> According to the classification system presented here, there were no patients with asymmetry solely in the ramus, and no patients had maxillary region asymmetry with one of the mandibular regions asymmetry. Although the reasons for and clinical significance of these results are still unclear, the asymmetry might be more advance in patients with ramus asymmetry.

This 3D-CT classification for facial asymmetry has the potential to replace the conventional method of classification using cephalograms because it permits more detailed evaluation. However, we should pay attention to the increased radiation exposure to patients which may occur as a result of such examinations. The dose reduction should be performed with preservation of sufficient image quality and may be accomplished through the use of a recently-available cone-beam CT.<sup>23-25</sup>

## REFERENCES

1. Fukushima K, Yasui K, Oatuka Y, Matsui S, Hirase N, Takayanagi J, et al. Morphological characteristics of patients with jaw deformity -Frontal cephalometric evaluation of facial symmetry-. *Meikai Univ Dent J*. 2003; 32:118-23.
2. Tani M, Iketani M, Watanabe M, Suda S, Fujimura N, Miyazawa M, et al. Posterior -anterior cephalometric analysis in patients with dentofacial deformities. *J Jpn Stomatol Soc*. 1989; 35:1749-59.
3. Severt TR, Proffit WR. The prevalence of facial asymmetry in the dentofacial deformities population at the University of North Carolina. *Int J Adult Orthodon Orthognath Surg*. 1997; 12:171-6.
4. Samman N, Tong AC, Cheung DL, Tideman H. Analysis of 300 dentofacial deformities in Hong Kong. *Int J Adult Orthodon Orthognath Surg*. 1992; 7:181-5.
5. Sassouni V. Diagnosis and treatment planning via roentgenographic cephalometry. *Am J. Orthodontics*. 1958; 44:433-63.
6. Ricketts RM. Cephalometric synthesis. *Am J. Orthodontics*. 1960; 46:647-73.
7. Mulick JF. Clinical use of the frontal headfilm. *Angle Orthod*. 1965; 35:299-304.
8. Graber TM. New horizons in case analysis-clinical cephalometrics. *Am J. Orthodont*. 1952; 38:603-24.
9. Graber TM. A critical review of clinical cephalometric radiography. *Am J. Orthodont*. 1954; 40:1-26.
10. Trpkova B, Prasad NG, Lam EW, Raboud D, Glover KE, Major PW. Assessment of facial asymmetries from posteroanterior cephalograms: validity of reference lines. *Am J Orthod Dentofacial Orthop*. 2003; 123:512-20.
11. Brown T, Abbott AH. Computer-assisted location of reference points in three dimensions for radiographic cephalometry. *Am J Orthod Dentofacial Orthop*. 1989; 95:490-8.
12. Grayson B, Cutting C, Bookstein FL, Kim H, McCarthy JG. The three-dimensional cephalogram: theory, technique, and clinical application. *Am J Orthod Dentofacial Orthop*. 1988; 94:327-37.
13. Kusnoto B, Figueroa AA, Polley JW. A longitudinal three-dimensional evaluation of the growth pattern in hemifacial microsomia treated by mandibular distraction osteogenesis: a preliminary report. *J Craniofac Surg*. 1999; 10:480-6.
14. Kawamata A, Arijii Y, Langlais RP. Three-dimensional computed tomography imaging in dentistry. *Dent Clin North Am*. 2000; 44:395-410.
15. Kawamata A, Arijii Y, Langlais RP. Three-dimensional imaging for orthognathic surgery and orthodontic treatment. *Oral Maxillofac Surg Clin North Am*. 2001; 13:713-25.
16. Xia J, Ip HH, Samman N, Wang D, Kot CS, Yeung RW, et al. Computer-assisted three-dimensional surgical planning and simulation: 3D virtual osteotomy. *Int J Oral Maxillofac Surg*. 2000; 29:11-7.
17. Katsumata A, Fujishita M, Maeda M, Arijii Y, Arijii E, Langlais RP. 3D-CT evaluation of facial asymmetry. *Oral Surg Oral Med Oral Pathol Oral Radiol Endod*. 2005; 99:212-20.
18. Cavalcanti MG, Haller JW, Vannier MW. Three-dimensional computed tomography landmark measurement in craniofacial surgical planning: experimental validation in vitro. *J Oral Maxillofac Surg*. 1999; 57:690-4.
19. Christiansen EL, Thompson JR, Kopp S. Intra- and inter-observer variability and accuracy in the determination of linear and angular measurements in computed tomography. An in vitro and in situ study of human mandibles. *Acta Odontol Scand*. 1986; 44:221-9.
20. Haraguchi S, Takada K, Yasuda Y. Facial asymmetry in subjects with skeletal class III deformity. *Angle Orthod*. 2002; 72:28-35.
21. Rachmiel A, Manor R, Peled M, Laufer D. Intraoral distraction osteogenesis of the mandible in hemifacial microsomia. *J Oral Maxillofac Surg*. 2001; 59:728-33.
22. Cho BC, Shin DP, Park JW, Baik BS. Bimaxillary osteodistraction for the treatment of facial asymmetry in adults. *Br J Plast Surg*. 2001; 54:491-8.
23. Schulze D, Heiland M, Thurmman H, Adam G. Radiation exposure during midfacial imaging using 4- and 16-slice computed tomography, cone beam computed tomography systems and conventional radiography. *Dentomaxillofac Radiol*. 2004; 33:83-6.
24. Schulze D, Heiland M, Blake F, Rother U, Schmelzle R. Evaluation of quality of reformatted images from two cone-beam computed tomographic systems. *J Craniomaxillofac Surg*. 2005; 33:19-23.
25. Araki K, Maki K, Seki K, Sakamaki K, Harata Y, Sakaino R, et al. Characteristics of a newly developed dentomaxillofacial X-ray cone beam CT scanner (CB MercuRay): system configuration and physical properties. *Dentomaxillofac Radiol*. 2004; 33:51-9.

## Reprint requests:

Eiichiro Arijii  
Department of Oral Radiology, Aichi-Gakuin University School of dentistry  
2-11, Suemori-dori, Chikusa-ku, Nagoya, Aichi pref., 464-8651, Japan  
TEL: +81 52 759 2165  
FAX: +81 52 759 2165  
ariji@dpc.aichi-gakuin.ac.jp